



Ultrasonographic Diagnosis and Surgical Removal of Unusual Palpebral Conjunctival Coenurus Cyst in a Kid

Patel Abhishek M*

Department of Veterinary Surgery and Radiology, College of Veterinary Science and Animal Husbandry, S. D. Agricultural University, Sardarkrushinagar, University in Palanpur, Gujarat, India

* Corresponding Author

Patel Abhishek M, Department of Veterinary Surgery and Radiology, College of Veterinary Science and Animal Husbandry, S. D. Agricultural University, Sardarkrushinagar, University in Palanpur, Gujarat, India, Tel: +919408424701, abhishepatel114@gmail.com

Citation

Patel Abhishek M (2026) Ultrasonographic Diagnosis and Surgical Removal of Unusual Palpebral Conjunctival Coenurus Cyst in a Kid. J Vet Sci Dairy Poult Res 1(1):106

Publication Dates

Received date: April 01, 2026

Accepted date: April 18, 2026

Published date: April 29, 2026

Abstract

A seven month old female kid was presented with bulging of right upper eyelid. Through clinical examination was performed and Trans-palpebral ultrasound examination revealed cyst. The circumscribed cyst was removed following a stab incision on mid of palpebral conjunctiva under local analgesia. Microscopic examination confirmed the coenurus cyst. The kid made an uneventful recovery.

Keywords: Coenurus Cyst; Kid; Palpebral Conjunctiva; Ultrasonography

Introduction

Coenurosis is an important disease affecting sheep and goat. In addition to its zoonotic impact, high economic losses in sheep and goat farms are also a noticeable effect of coenurosis. *Coenurosis cerebri* is a principal cause for nervous manifestations due to manifestation in the Central nervous system [1]. Further, in non-cerebral coenurosis, the larval form of the *Taenia multiceps gaei* which is a cestode of wild and domestic canids have also been reported [2]. *C. gaei* is commonly reported in the shoulder, thigh, kidney, neck muscle, heart, diaphragm, uterus, rectum and urinary bladder [3], retro-bulbar eye [4], lower eyelid [5], peri-orbital of domestic goats [6]. Ultrasonographical diagnosis along with surgical management of coenurosis has been described by [7]. Unusual palpebral conjunctival coenurosis cyst's surgical management in a kid is reported here.

Materials and Methods

A seven months old surti male kid was presented at the veterinary

clinical complex, deesa, SDAU with the history of unilateral bulging of right upper eyelid since one month, Blepharitis and congestion of conjunctiva membrane was noticed (Figure 1).

Clinical examination of the kid revealed normal physiological body parameter viz., rectal temperature (101.5F), heart rate (86 per minute) and respiratory rate (33 per minute) and conjunctival mucus membrane was pink. The protrusion of swelling was from perorbitum (below upper eyelid) over cornea of right eye ball. Palpation revealed a soft, fluctuating, non-painful cyst. This swelling was hindrance in vision due to the protrusion but the vision was not imparted. On needle paracentesis a clear fluid was observed.

Ultrasonographic examination was performed after restraining of kid, using a 6–8 MHz convex transducer. Ultrasonography of the affected eye confirmed the presence of a circumscribed anechoic area due to watery consistency in the retro bulbar muscle (Figure 2).

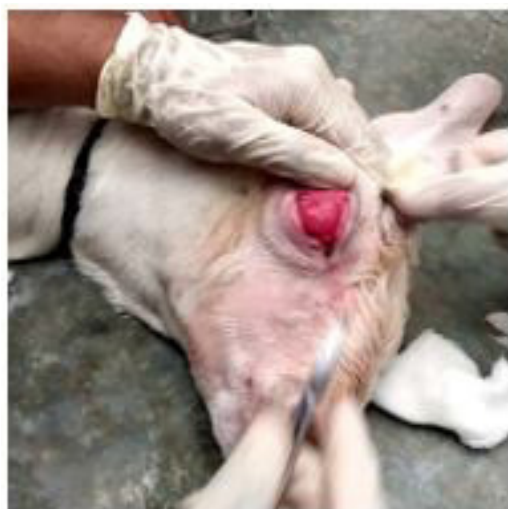

Figure 1: Blepharitis and congestion of conjunctiva membrane

Clinical examination, ultrasonographic examination and needle paracentesis confirmed the cyst.

The cyst was surgically removed by a stab incision under local infiltration of 2% lignocaine hydrochloride on mid part of swelling (Figure 3). The cyst was successfully removed intact along with its membrane. Colour less transparent fluid was drained out after removal of cyst. The cavity was flushed with normal saline. Macroscopic investigation revealed proscolices in clusters attached to the internal surface of its wall (Figure 4).

Post-surgical management carried out by Drop. Gentamicin

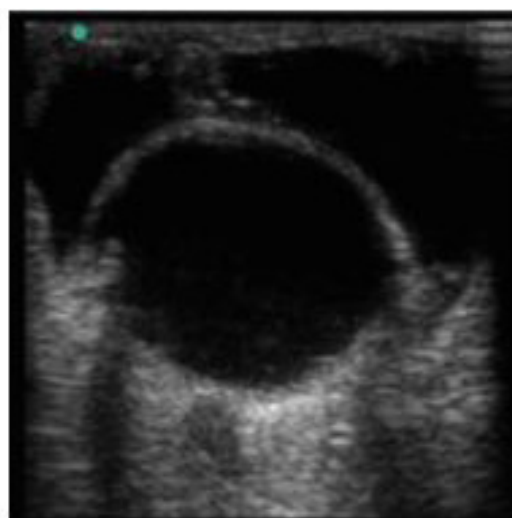


Figure 2: Ultrasonography of the affected eye

0.3% TID, for five days, Inj. Meloxicam @ 0.2mg/kg, IM for five days, Tab. Fentas 150mg, orally and it repeated after 21 days.

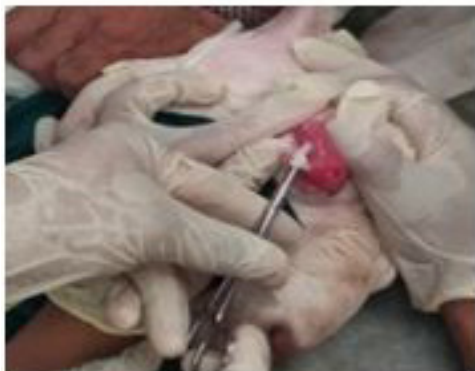

Figure 3: Cyst was surgically removed by a stab incision

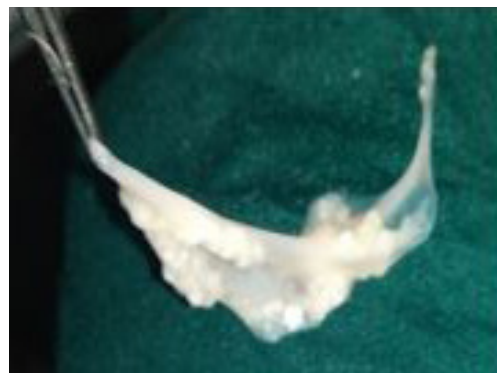

Figure 4: Proscolices in clusters attached to the internal surface

Results and Discussion

The animal resumed normal posture and vision (Figure 6). The cyst measured 2.3 cm × 2.8 cm and contained large amount of fluid with numerous invaginated proscolices (Figure 4). Microscopic view of single proscolice revealed the typical taenid hooks that characteristically conforms coenurus (Figure 5) located extra cranial found in the intermediate stage of *T. multiceps gaigeri* [8].

On the basis of clinical signs, physical examination, ultrasonographical imaging, needle paracentesis and parasitic examination the retro-bulbar cyst which was confirmative diagnosed a *Coenurus gaigeri*.

Coenurosis is an important disease affecting sheep and goat which causes significant economic losses in their production. The metacestode stage of *Taenia multiceps* is associated with coenurosis. The cerebral form of coenurosis, also known as Gid or sturdy. The cystic larvae develop in the brain and spinal cord of the parasitized host and there by affect the normal functioning of the central nervous system [2,9]. Contrary to above, occasionally aberrant sites of predilection of the metacestode, especially in goats, with an alternate name (*C. gaigeri*), have been documented [8,10,11].

In a majority of coenurie affected goats, the cysts anchor, develop, mature and cause asymptomatic focal lesions in extra cranial aberrant sites. The lesions often persist throughout the life span of the host [2]. *Coenurus gaigeri* is the larval stage of *Taenia multicepsgaigeri*, which belongs to the class Cestoda, order Cyclophyllidae, family Taenidae and genus *Multiceps*

[12]. Such animals are potentially important source of the disease in growing animals and/or of zoonotic significance. Goats, being intermediate host usually get the infection from the dog's excreta therefore the treatment of dogs in and around the farms for tapeworm should be made [13]. Entry of street dogs to goat peddocks should be prevented for control of this ailment. Adult goats are slaughtered for human consumption. Humans are dead-end intermediate hosts and become infected by ingesting eggs passed in the excrement of a definitive host. The ingested eggs release oncospheres in the host intestine that penetrate the intestinal wall and migrate toward target organs through the blood stream, usually lodging in the brain, spinal canal, or eye [14]. The dogs in and around the animal farms should be treated with anthelmintics to prevent the spread of infection to the farm animals. Prophylactic antihelminthic therapy can be given to the small ruminants but the economic feasibility must also be considered. Albendazole or combinations of anthelmintics (Fenbendazole and Praziquantel) were useful in coenurosis [15-18].

Acknowledgments

The authors are thankful to The Dean, College of veterinary science and animal husbandary, SDAU, Gujarat, India for providing all facilities to carry out the investigation.

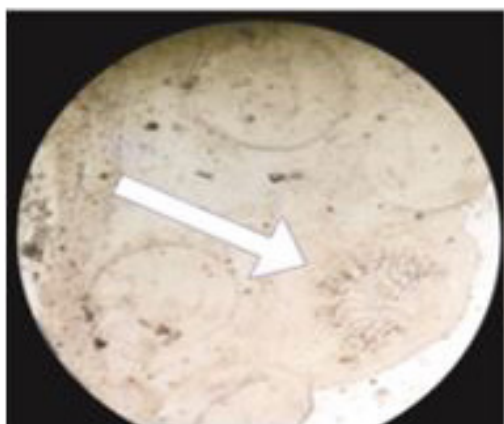


Figure 5: Microscopic view of single prosclex revealed the typical taenid hooks

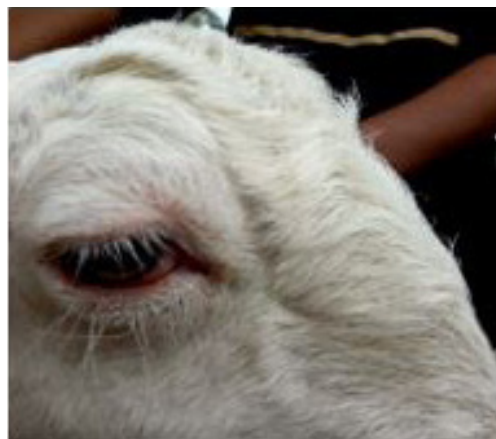

Figure 6: Animal resumed normal posture and vision

References

1. Desouky EA, Badawy AI, Refaat RA (2011) Survey on coenurosis in sheep and goats in Egypt. *Vet Italiana* 47: 333-40.
2. Sharma DK, Chauhan PPS (2006) Coenurosis status in Afro-Asian region: a review. *Small Rumin Res* 64: 197-202.
3. Varma TK, Malviya HC (1989) Prevalence of coenurosis in sheep, goat and pig in Bareilly, Uttar Pradesh. *J Vet Parasitol* 3: 69.
4. Sharma N, Kumar A, Chaturvedi V, Nayakwadi S, Mishra AK, et al. (2017) Retro-bulbar cyst of *Coenurus gaigeri* in Barbari goats. *J Parasit Dis* 41: 367-70.
5. Raidurg R, Reddy PMT (2009) Parasitic cyst (*Coenurus gaigeri*) in the lower eyelid of a kid-a case report. *Intas Polivet* 10: 302-3.
6. Aher VD, Avhad C, Jadhav S, Balage PR, Lokhande DS, et al. (2018) A rare case of peri-orbital *Coenurus gaigeri* cyst in a goat and its surgical management. XLII annual congress of Indian Society for Veterinary Surgery & National Symposium.
7. Biswas D (2013) Ultrasound diagnosis and surgical treatment of coenurosis (GID) in Bengal goat (*Capra hircus*) at Chittagong metropolitan area, Chittagong, Bangladesh. *Sci J Vet Adv* 2: 68-75.
8. Madhu DN, Mahan T, Sudhakar NR, Maurya PS, Banerjee PS, et al. (2014) *Coenurus gaigeri* cyst in the thigh of a goat and its successful management. *J Parasit Dis* 38: 286-8.
9. Aiello SE, Mays A (1998) *The Merck Veterinary Manual* (8th Edn) Merck & Co Inc. New Jersey, USA.
10. Sharma DK, Sanil NK, Agnihorti MK, Singh N (1995) Subcutaneous coenurosis in Barbari goat. *Indian Vet J* 72: 1203-5.
11. Kumar N, Aithal HP, Gupta SC, Mogha IV (2003) Occurrence of unusually large *Coenurus* cyst in subcutaneous tissues of sheep. *J Vet Parasitol* 17: 73-4.
12. Soulsby EJJ (1982) *Helminths, arthropods and protozoa of domesticated animals*, 7 London: Bailliere Tindall and Cassell Ltd, UK.
13. Ozkan C, Yildirim S, Kays A (2011) Clinical coenurosis (*Coenurus cerebralis*) and associated pathological findings in a calf. *Pakistan Vet J* 31: 263-6.
14. Abera S, Wubit T, Nejash A (2016) Cerebral Coenurosis in Small Ruminants: A Review. *Journal of Animal Science Advances* 6: 1595-608.
15. Ghazaei C (2005) Evaluation of the effect of anthelmintic agents albendazole, fenbendazole and praziquantel in treatment of coenurosis disease in sheep. *Journal of Animal Science Advances* 4: 852-4.
16. Gahlot TK, Purohit S (2005) Surgical management of gid (coenurosis) in goat: case report. *Intas Polivet* 6: 297-8.
17. Nandi SK, Pal A (2001) Successful surgical management of cyst in goat: a case report. *Indian J Anim Health* 40: 83-4.
18. Paliwal OP, Singh SP, Singh KP (1971) Multiceps cyst over a kidney of a goat. *Indian Vet J* 48: 1278-9.